

Respiratory Nematodiases in Raptors in Quebec

Authors: Martin Lavoie, Igor Mikaelian, Mauritz Sterner, Alain Villeneuve, Guy Fitzgerald, et. al.

Source: Journal of Wildlife Diseases, 35(2) : 375-380

Published By: Wildlife Disease Association

URL: <https://doi.org/10.7589/0090-3558-35.2.375>

BioOne Complete (complete.BioOne.org) is a full-text database of 200 subscribed and open-access titles in the biological, ecological, and environmental sciences published by nonprofit societies, associations, museums, institutions, and presses.

Your use of this PDF, the BioOne Complete website, and all posted and associated content indicates your acceptance of BioOne's Terms of Use, available at www.bioone.org/terms-of-use.

Usage of BioOne Complete content is strictly limited to personal, educational, and non-commercial use. Commercial inquiries or rights and permissions requests should be directed to the individual publisher as copyright holder.

BioOne sees sustainable scholarly publishing as an inherently collaborative enterprise connecting authors, nonprofit publishers, academic institutions, research libraries, and research funders in the common goal of maximizing access to critical research.

Respiratory Nematodiasis in Raptors in Quebec

Martin Lavoie,¹ Igor Mikaelian,¹ Mauritz Sterner,² Alain Villeneuve,³ Guy Fitzgerald,⁴ John D. McLaughlin,⁵ Stéphane Lair,¹ Daniel Martineau,^{1,6} Canadian Cooperative Wildlife Health Centre and Centre Québécois sur la Santé des Animaux Sauvages, Département de Pathologie et de Microbiologie, Faculté de Médecine Vétérinaire, Université de Montréal, Saint-Hyacinthe, J2S 7C6, Québec, Canada; ² University of Nebraska State Museum, Division Parasitology, Harold W. Manter Laboratory, 529-W Nebraska Hall, Lincoln, Nebraska 68588-0514, USA; ³ Département de Pathologie et de Microbiologie, Faculté de Médecine Vétérinaire, Université de Montréal, Saint-Hyacinthe, J2S 7C6, Québec, Canada; ⁴ Clinique des Oiseaux de Proie, Faculté de Médecine Vétérinaire, Université de Montréal, Saint-Hyacinthe, J2S 7C6, Québec, Canada; ⁵ Department of Biology, Concordia University, Montréal, H3G 1M8, Québec, Canada; ⁶ Corresponding author (email: martineau@ere.umontreal.ca).

ABSTRACT: This is a retrospective study on wild raptors submitted to the Université de Montréal (Quebec, Canada) from 1989 to 1996. *Cyathostoma* spp. (Nematoda: Syngamidae) adults and/or eggs were found in air sacs, lungs, bronchi, and trachea of 12 raptors (Falconiformes and Strigiformes) from Quebec, Canada, belonging to eight different species, five of which are first host records for this parasite: barred owl (*Strix varia*), snowy owl (*Nyctea scandiaca*), northern harrier (*Circus cyaneus*), northern goshawk (*Accipiter gentilis*), and broad-winged hawk (*Buteo platypterus*). The infection was considered fatal in four birds, while no significant clinical signs were observed in the other cases. Major pathologic changes included diffuse pyogranulomatous air sacculitis, pneumonia, and bronchitis. A few unidentified larval nematodes embedded in a granuloma were found in the lungs of an additional Cooper's hawk (*Accipiter cooperii*); they were not considered clinically significant. A dead nematode, surrounded by necrotic inflammatory cells, was found in the air sac of a northern goshawk. The presence of nematodes in air sacs or lungs should be considered in wild raptors demonstrating respiratory problems.

Key words: Air sacculitis, *Cyathostoma* spp., Falconiformes, lung, nematode, Strigiformes, survey.

Infection of the lower respiratory tract by nematodes is rarely identified in birds of prey. *Serratospiculum* sp. (Diplotriae-noidea) is the most frequently encountered species. It occurs mainly in prairie falcons (*Falco mexicanus*) (Bigland et al., 1964; Ward and Fairchild, 1972; Croft and Kingston, 1975) and occasionally in other raptorial species (Bain and Vassiliades, 1969; Kocan and Gordon, 1976; Sterner and Espinosa, 1988; Ackerman et al., 1992; Taft et al., 1994). The syngamid nematodes *Cyathostoma* sp. (Hunter et al.,

1993) and *Syngamus* sp. (Smith, 1993) also occur in raptors, but they seem less common.

The life cycles of species of *Cyathostoma* and *Syngamus* are similar. Adult nematodes live in air sacs, lungs, or trachea and produce operculate eggs in which infective third-stage larvae develop. Birds cough up the ova which are then swallowed and passed in the feces. Birds acquire syngamid infections by ingesting eggs containing infective larvae. Furthermore, arthropods and earthworms feeding on contaminated material often serve as paratenic hosts (Fernando et al., 1971, 1973a; Simpson and Harris, 1992). These parasites are usually of little consequence for the avian host (Kocan and Gordon, 1976), although they are occasionally clinically significant (Hunter et al., 1993; Watters et al., 1994).

This report reviews cases of wild raptors brought for necropsy from 1989 to 1996 at the Faculté de Médecine Vétérinaire (Université de Montréal, Saint-Hyacinthe, Québec, Canada) and found infected with lower respiratory tract nematodes. The study includes 15 raptors belonging to nine species. The barred owl (*Strix varia*), snowy owl (*Nyctea scandiaca*), northern harrier (*Circus cyaneus*), northern goshawk (*Accipiter gentilis*), and broad-winged hawk (*Buteo platypterus*) are new host records for *Cyathostoma* sp.

Since 1993, all information from wildlife submissions to the Université de Montréal and Quebec provincial laboratories have been recorded in the database of the Canadian Cooperative Wildlife Health Cen-

tre (Department of Veterinary Pathology, Western College of Veterinary Medicine, Saskatoon, Saskatchewan, Canada). This study is based on an examination of this database from 1993 to 1996 and from cases recorded from 1989 to 1992 by the Clinique des Oiseaux de Proie (COP; Faculté de Médecine Vétérinaire, University of Montreal, Saint-Hyacinthe, Quebec, Canada).

All birds were wild-caught specimens from Quebec and were referred to us through a raptor rehabilitation network, the Union québécoise de réhabilitation des oiseaux de proie (Faculté de Médecine Vétérinaire.)

Samples were taken from major organs and organs demonstrating gross morphologic changes. Specimens were fixed in 10% buffered formalin and were routinely processed for histopathology. All slides were reevaluated prior to publication by the same pathologist (IM).

Parasites were fixed in a mixture of 5% glycerine in 70% ethanol. *Cyathostoma americanum* infection was diagnosed when adult male parasites were found at necropsy. *Cyathostoma* sp. infection was diagnosed when adult female parasites were found at necropsy or when typical eggs were found in tissues at histologic examination. Lung granulomas were classified as parasitic granulomas only if they contained parasites or parasite remnants.

From 1993 to 1996, a total of 394 birds of prey representing 24 species were examined. Among these birds, 14 from eight species had lower respiratory tract nematodes (Table 1). Material from COP provided three additional birds prior to 1993 but postmortem information from these birds was limited.

Twelve birds were infected with *Cyathostoma* spp. and two birds were infected with unidentified adult or larval nematodes (Table 2). Representative specimens of *Cyathostoma* spp. were archived at the Canadian Museum of Nature and at the University of Nebraska State Museum (Table 2). Adults or eggs of *Cyathostoma*

TABLE 1. Prevalence of *Cyathostoma* spp. infection in raptors from Quebec, 1993 to 1996.

Host	Number infected/ Number examined (%)
Northern goshawk	3/16 (19)
Cooper's hawk	1/7 (14)
Broad-winged hawk	2/24 (8)
Merlin	1/24 (4)
Boreal owl	1/3 (33)
Northern saw-whet owl	3/20 (15)
Barred owl	1/13 (8)
TOTAL	23/107 (11)

spp. were observed in 1 barred owl, 1 boreal owl (*Aegolius funereus*), 2 broad-winged hawks, 1 merlin (*Falco columbarius*), 3 northern goshawks, 1 northern harrier (*Circus cyaneus*), 2 northern saw-whet owls (*Aegolius acadicus*) and 1 snowy owl (Table 2).

No preferential location in air sacs was found for *Cyathostoma* spp. adults. In four of 12 birds, only eggs were recovered while adults and eggs were present in the remaining eight birds. Female *Cyathostoma* spp. were 1–1.5 mm in diameter and 2.5–3 cm in length, red with undulating white reproductive tracts (ovary, oviduct) giving an appearance of a barber's pole. Male *C. americanum* measured 0.5 mm in diameter and 1–1.5 cm in length, and were uniformly bright red. Eggs were ellipsoidal, smooth-walled, possessed a polar plug at each end and contained a morula. They were approximately the same size in all birds and measured approximately 80 μ m in length and 45 μ m in width.

Four birds presented clinical signs attributed to cyathostomiasis which resulted in their hospitalization. Main clinical signs were emaciation (4/4) and/or dyspnea (2/4). Adult parasites were found in three of four of these birds. The major pathologic change in clinically affected birds was severe diffuse pyogranulomatous air sacculitis (4/4; Fig. 1). In a barred owl, all the air sacs of the skull were filled by a thick fibrino-purulent material that contained *Cyathostoma* sp. eggs. The animal was

TABLE 2. Nematodiasis in birds of prey from Quebec.

Species	Cause of admission	Parasite	Intensity ^f	Major respiratory tract findings
Barred owl ^a	Emaciation	<i>Cyathostoma</i> sp.	2	Severe pyogranulomatous air-sacculitis (skull air sacs)
Boreal owl	Dyspnoea	<i>Cyathostoma</i> sp.	0 ^d	Marked multifocal pyo-granulomatous air-sacculitis and perihepatitis
Broad-winged Hawk ^a	Trauma	<i>Cyathostoma</i> sp.	0 ^d	Marked focal pyo-granulomatous air-sacculitis, moderate focally extensive granulomatous bronchitis
Broad-winged Hawk ^a	Emaciation	<i>C. americanum</i> HWML 39518 ^b	20 ^e	Severe multifocal pyo-granulomatous pneumonia and air sacculitis
Merlin	Trauma	<i>Cyathostoma</i> sp.	0 ^d	Diffuse moderate granulomatous air-sacculitis
Northern Goshawk ^a	Emaciation	<i>Cyathostoma</i> sp.	2	Minimal focal granulomatous pneumonia
Northern Goshawk ^a	Trauma	<i>Cyathostoma</i> sp.	3	Minimal focal granulomatous bronchitis
Northern Goshawk ^a	Emaciation, dyspnoea	<i>C. americanum</i> CMNP 1994-0097 ^c	100 ^e	Severe pyo-granulomatous air-sacculitis and pneumonia (gross pathology)
Northern Harrier ^a	Trauma	<i>Cyathostoma</i> sp. CMNP 1994-0098 ^c	2	No change (gross pathology)
Northern Saw-whet Owl	Trauma	<i>Cyathostoma</i> sp.	0 ^d	Marked focal pyo-granulomatous bronchitis
Northern Saw-whet Owl	Trauma	<i>Cyathostoma</i> sp. CMNP 1994-0095 ^c	3	Minimal focal granulomatous air-sacculitis
Snowy Owl ^a	Emaciation	<i>Cyathostoma</i> sp. CMNP 1994-0094 ^c	6	Severe pyo-granulomatous air-sacculitis (gross pathology)
Cooper's Hawk	Trauma	nematode larvae	0 ^d	Minimal multifocal granulomatous pneumonia
Northern Goshawk	Trauma	unidentified adult nematode	0 ^d	necrotic nematode in a free mass in a thoracic air sac

^a New host records.

^b Canadian Museum of Nature, Ottawa, Ontario, Canada.

^c Harold W. Manter Laboratory, University of Nebraska State Museum, Lincoln, Nebraska, USA.

^d Identification based on the presence of eggs.

^e Numbers approximate.

^f Count of adult parasites.

emaciated but it could not be determined whether the parasitic infection was causally related to the emaciation. In seven infected birds with no clinical manifestation, air sacculitis was either absent (4), diffuse and minimal (1) to mild (1), or marked but focal (1).

In a broad-winged hawk, the only sign of cyathostomiasis was a 2 cm diameter firm, dark-brown mass on the surface of the liver. Upon histologic examination, this mass was identified as a pyogranuloma

which contained a few eggs typical of *Cyathostoma* spp. and numerous Gram-positive bacteria, which were not cultured.

Upon histologic examination, *Cyathostoma* spp. eggs were found in the lungs (8/8), air sacs (5/10) and digestive tract (5/7). Eggs generally elicited pyogranulomatous bronchitis or pneumonia in the lungs (6/8) although no inflammation was noted in two cases. Lung and air sac lesions were occasionally associated with *Aspergillus* sp. hyphae (1/10) or bacterial

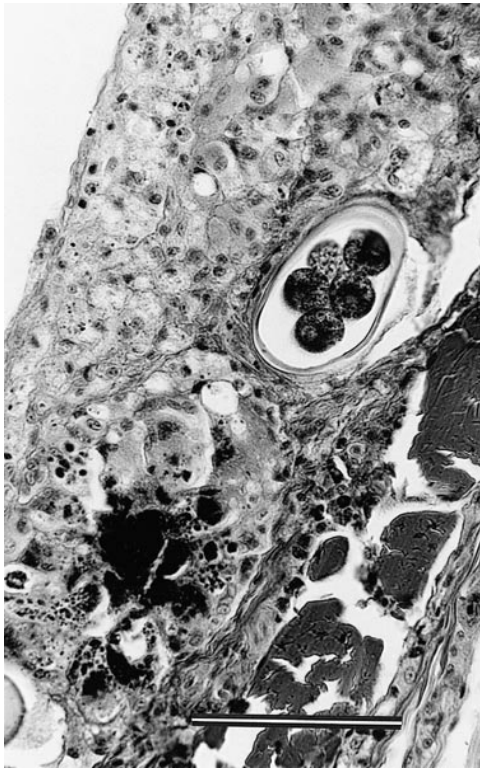


FIGURE 1. Histological section of air sac of a broad-winged hawk showing diffuse marked pyogranulomatous air sacculitis. An embryonated nematode egg and cocci colonies are present. Hematoxylin-phloxin-saffron. Bar = 80 μ m.

colonies (3/10; Fig. 1). These bacteria were not cultured.

Two birds were infected with air tract nematodes other than *Cyathostoma* sp. They did not show evidence of respiratory impairment or emaciation. A few small granulomas were found centered on an unidentified 20 μ m-diameter nematode larva in the lungs of a Cooper's hawk (*Accipiter cooperii*). These lesions were not considered clinically significant. A 3 \times 5 mm mass was found unattached in a thoracic air sac of a northern goshawk. This mass contained several sections of an unidentified, dead, 90 μ m-diameter nematode. The parasite was surrounded by considerable numbers of macrophages and degenerated leukocytes, three to four cells in depth.

Nematodes of the genus *Syngamus* and

Cyathostoma parasitize the respiratory tract of a variety of avian species. Eggs from these two genera are morphologically similar. However, no *Syngamus* sp. was recognized clinically or at necropsy in over 2,000 birds of prey admitted at the COP between 1989 and 1996 (G. Fitzgerald, pers. obs.). During the same period, from a total of over 600 non-raptorial birds, *S. trachea* occurred in three american robins (*Turdus migratorius*), all from the same clutch. For this reason, all syngamid eggs found in birds of prey were attributed to the genus *Cyathostoma*. In two of the birds from the present study, male *Cyathostoma* sp. were present and the parasites were identified as *C. americanum*. Unfortunately, in the other six birds with adult *Cyathostoma* sp., the absence of male specimens precluded species identification of the parasite.

Although cyathostomiasis in birds is rare, three species have been reported in birds of prey: *C. americanum* (Soulsby, 1965), *C. brodskii* (Ryzhikov, 1980) and *C. lari* (Simpson and Harris, 1992). Fatal infection is exceptional but it has been reported in a wild eagle owl (*Bubo bubo*) in Switzerland (Mumcuoglu and Mueller, 1974) and in a northern saw-whet owl and in captive screech owls (*Otus asio*) in Canada (Hunter et al., 1993). This report presents five new host records and suggests that clinical infection could occur in most species of raptors. In severe cases, secondary bacteria and fungi within some lesions may have stimulated a greater host response than eggs or adults alone.

The digestive tract is the normal route of excretion for *Cyathostoma* sp. eggs (Soulsby, 1965; Ruff, 1984). Gravid adults and ova were observed more often within air sacs than in the upper respiratory tract. Hunter et al. (1993) proposed that this distribution of eggs may indicate that *Cyathostoma* sp. is not well adapted to Strigiformes. Raptors are likely aberrant hosts for *Cyathostoma* sp. given the low prevalence (12/394) and aberrant location of adult parasites in air sacs, since the pre-

ferred location in host species is the trachea or lungs (Fernando et al. 1971, 1973b).

In the cases described herein, clinical infection was found in Strigiformes as well as in Falconiformes. Since the life history of *Cyathostoma* sp. involves earthworms as paratenic hosts (Soulsby, 1965; Fernando et al., 1973a; Ruff, 1984), it is surprising to find infections in birds such as the merlin (*Falco columbarius*), the northern goshawk and the snowy owl, species that generally do not feed on invertebrates. In these cases, it is more likely that infection was transmitted through ingestion of infected invertebrates present in the alimentary tract of prey species, as suggested for *C. lari* infections in sparrowhawks (*Accipiter nisus*) (Simpson and Harris, 1992).

Parasitic granulomas with unidentified nematodes were found in air sacs of a northern goshawk and in lungs of a Cooper's hawk. The two available descriptions of nematodes other than *Cyathostoma* sp. in the lungs of birds are associated with visceral larva migrans of *Baylisascaris procyonis* (Kazacos et al., 1982) and *B. transfuga* (Papini et al., 1993). In both cases, larva migrans elicited a pyogranulomatous pneumonia. However, in the latter cases as well as in the present report, visceral granuloma were not considered contributory to the birds' condition.

We thank R. C. Anderson for assistance with the identification of *Cyathostoma* sp. We are grateful to J. Cardin, J. Deslandes, C. Lussier, L. Pépin and B. Pépin-Faille for skillful laboratory assistance. This study was funded by the Canadian Cooperative Wildlife Health Centre, Saskatoon, Saskatchewan, Canada and by the Centre Québécois sur la Santé des Animaux Sauvages, Saint-Hyacinthe, Quebec, Canada. Major contributors to these two organizations are Environnement Canada, the Ministère de l'Environnement et de la Faune du Québec, the Canadian Wildlife Federation, Ducks Unlimited Canada, AgrEvo Canada Inc., DowElanco Canada

Inc., Novartis Crop Protection Inc. and the Max Bell Foundation.

LITERATURE CITED

- ACKERMAN, N., C. ISAZA, E. GREINER, AND C. R. BERRY. 1992. Pneumocoelom associated with *Serratospiculum amaculata* in a bald eagle. *Veterinary Radiology and Ultrasound* 33: 351–355.
- BAIN, O., AND G. VASSILIADES. 1969. Cycle évolutif d'un *Dicheilonematinae*, *Serratospiculum tendo*, Filaire parasite du faucon. *Annales de Parasitologie* 44: 595–604.
- BIGLAND, C. H., L. SI-KWANG, AND M. L. PERRY. 1964. Five cases of *Serratospiculum amaculata* (Nematoda: Filarioidea) infection in prairie falcons (*Falco mexicanus*). *Avian Diseases* 8: 412–419.
- CROFT, R. E., AND N. KINGSTON. 1975. *Babesia moshkoviskii* (Schurenkova, 1938) Laird and Lari, 1957; from the prairie falcon, *Falco mexicanus*, in Wyoming; with comments on other parasites found in the host. *Journal of Wildlife Diseases* 11: 229–233.
- FERNANDO, M. A., P. H. STOCKDALE, AND O. REMMLER. 1971. The route of migration, development, and pathogenesis of *Syngamus trachea* (Montagu, 1811) Chapin, 1925, in pheasants. *The Journal of Parasitology* 59: 107–116.
- , I. J. HOOVER, AND S. G. OGUNGBADE. 1973a. The migration and development of *Cyathostoma bronchialis* in geese. *The Journal of Parasitology* 59: 759–764.
- , P. H. STOCKDALE, AND S. G. OGUNGBADE. 1973b. Pathogenesis of the lesions caused by *Cyathostoma bronchialis* in the respiratory tract of geese. *The Journal of Parasitology* 59: 980–986.
- HUNTER, D. B., K. MCKEEVER, AND C. BARTLETT. 1993. *Cyathostoma* infections in screech owls, saw-whet owls, and burrowing owls in southern Ontario. *In Raptor Biomedicine*, P. T. Redig, J. E. Cooper, J. D. Remple, and D. B. Hunter (eds.). University of Minnesota Press, Minneapolis, Minnesota, pp. 56–57.
- KAZACOS, K. R., E. A. KAZACOS, J. A. RENDER, AND H. L. THACKER. 1982. Cerebrospinal nematodiasis and visceral larva migrans in an Australian (Latham's) brush turkey. *Journal of the American Veterinary Medical Association* 181: 1295–1298.
- KOCAN, A. A., AND L. R. GORDON. 1976. Fatal air sac infection with *Serratospiculum amaculata* in a prairie falcon. *Journal of the American Veterinary Medical Association* 169: 908.
- MUMCUOGLU, Y., AND R. MUELLER. 1974. Parasitische milben und wurmer als todesursache eines uhus *Bubo bubo*. *Der Ornithologische Beobachter* 71: 289–292.
- PAPINI, R., P. CAVICCHIO, AND L. CASAROSA. 1993. Experimental infection in chickens with larvae of

- Baylisascaris transfugea* (Nematoda: Ascaroidea). *Folia Parasitologica* 40: 141–143.
- RUFF, M. D. 1984. Nematodes and Acanthocephalans. In *Diseases of poultry*, 8th Edition. H. J. Barnes, B. W. Clanek, W. M. Reid, and H. W. Yoder (eds.). Iowa State University Press, Ames, Iowa, pp. 614–648.
- RYZHIKOV, K. M. 1980. The biology of a nematode *Cyathostoma bronchialis* (Syngamidae: Strongylata). *Helminthologia* 17: 241–244.
- SIMPSON, V. R., AND A. H. HARRIS. 1992. *Cyathostoma lari* (Nematodoma) infection in birds of prey. *Journal of Zoology* 227: 655–659.
- SMITH, S. A. 1993. Diagnosis and treatment of heminths in birds of prey. In *Raptor biomedicine*, P. T. Redig, J. E. Cooper, J. D. Remple, and D. B. Hunter (eds.). University of Minnesota Press, Minneapolis, Minnesota, pp. 21–27.
- SOULSBY, E. J. L. 1965. *Textbook of veterinary clinical parasitology*. Blackwell Scientific Publications, Oxford, UK, 1120 pp.
- STERNER, M. C., AND R. H. ESPINOSA. 1988. *Serratospiculoides amaculata* in a Cooper's hawk (*Accipiter cooperii*). *Journal of Wildlife Diseases* 24: 378–379.
- TAFT, S. J., R. N. ROSENFELD, AND J. BIELEFELDT. 1994. Avian hematozoa of adult and nestling Coopers' hawk (*Accipiter cooperii*) in Wisconsin. *Journal of the Helminthological Society of Washington* 61: 146–148.
- WARD, F. P., AND D. G. FAIRCHILD. 1972. Air sac parasites of the genus *Serratospiculum* in falcons. *Journal of Wildlife Diseases* 8: 165–168.
- WATTERS, C. E., K. L. JOYCE, S. E. HEATH, AND K. R. KAZACOS. 1994. *Cyathostoma* infection as the cause of respiratory distress in emus (*Dromaius novaehollandiae*). In *Association of Avian Veterinarians, Proceedings of the annual conference of the Association of Avian Veterinarians*, Boca Raton, Florida, pp. 151–155.

Received for publication 8 June 1998.